

Swept-Source OCT: A new manner to study retina and choroid

By Dr Iñaki Flores-Moreno, PhD, and Dr JM Ruiz-Moreno, PhD, Castilla La Mancha University, Spain.

Swept-Source optical coherence tomography (SS-OCT) has revolutionized our capability to study deeper layers of the eye, such as the choroid and sclera. This new technology allows for better resolution imaging when studying chorioretinal diseases as a result of the longer wavelength employed [around 1050 nm, compared to 800 nm used in previous technologies, such as time-domain or spectral-domain (SD)], higher number of scans that can be averaged, higher image capture rate and uniform image quality over depth. The long scan, provided by the Topcon DRI-1 OCT Atlantis (Topcon Corporation, Japan), up to 12 mm, permits simultaneous study of the macular area and the optic nerve.

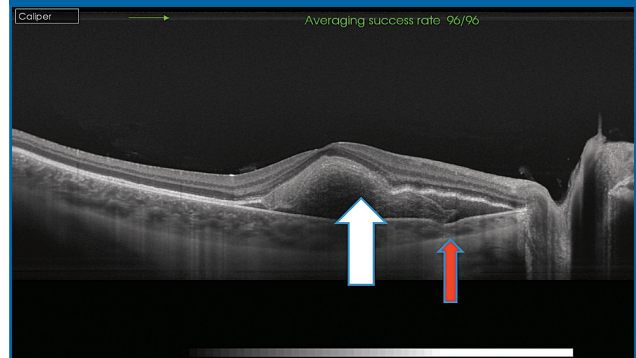
The effect of ageing in the choroid has been demonstrated to reduce its thickness in healthy patients. Therefore, in theory, a paediatric population should have a full macula choroidal thickness when compared with adults, but our research group demonstrated that paediatrics only have a thicker temporal choroid. The paediatric choroidal profile shows that the thickest part of the choroid is in the temporal region of the macula and this decreases as far as it is measured nearing the optic nerve. There is a decrease in thickness of the temporal area of the macula during the first decade of life until the subject's twenties, when the choroidal profile adopts a similar one to that of adults, with a thicker choroid in the subfoveal area, decreasing in the temporal region and being thinnest in the nasal area, becoming thinner the closer you get to the optic disc.¹

SS-OCT is particularly useful in really thick choroids, which can occur in central serous chorioretinopathy, polypoidal choroidal vasculopathy or young and healthy hyperopic patients. In such cases, difficulties in imaging the choroid-scleral interface can be encountered with SD OCT, whereas, SS-OCT allows for a better visualization in thicker choroids.^{1,2} Good correlation has been demonstrated between SD and SS-OCT in healthy patients, although extrapolation of the data should be taken with caution because of the differences in choroidal-scleral interface visualization.²

SS-OCT provides excellent images of not only deeper structures but also the vitreoretinal interface.³ *In vivo* vitreous anatomy is possible due to SS technology. *Bursa premacularis* is seen in more than half of a large population with an age range from 5 to 100 years old.³ There is a positive correlation between the presence of *bursa premacularis* and the space of Mortegiani³ and a continuity between the bursa and Mortegiani prepapilar space has been identified with SS-OCT.⁴

To conclude, SS-OCT permits a better visualization of all the posterior pole structures including the vitreous, retina, choroid, sclera and optic disc, which will help ophthalmologists understand the physiopathology of ocular

Figure 1: We can see a choroidal and retinal pigmentary epithelium rupture (red arrow) , through a sub-retinal haemorrhage (white arrow). Usually it is not possible with SD-OCT due to the blood presence.



diseases involving these structures and could facilitate the development of new drugs and treatments.

References

1. J.M. Ruiz-Moreno *et al.*, *Invest. Ophthalmol. Vis. Sci.*, 2013;**54**:353–359.
2. S. Copete *et al.*, *Br. J. Ophthalmol.*, 2014;**98**:334–338.
3. P.E. Stanga *et al.*, *Am. J. Ophthalmol.*, 2014. [Ahead of print.]
4. K.B. Schaal *et al.*, *Ophthalmology*, 2014. [Ahead of print.]



Topcon Europe Medical BV

Essebaan 11, 2908 LJ
Capelle aan den IJssel, The Netherlands

Tel.: +31 10 4585077

E-mail: medical@topcon.eu

Website: www.topcon-medical.eu

Swept Source, the 3rd Generation of OCT

Imaging the depths of the eye

Topcon has developed a Swept Source OCT, the 3rd generation of Optical Coherence Tomography. The DRI OCT-1 incorporates Swept Source OCT technology that enhances the visualization of the choroid and, for the first time, enables you to visualize the vitreous, retina and choroid in high resolution on the same scan.

1050 nm wavelength

The Topcon DRI OCT-1 uses a wavelength of 1050 nm, which is much higher than the conventional 850 nm used in Spectral Domain-OCT. This increase in wavelength penetrates tissue better, with less scatter. Therefore you are able to image deeper structures better. There is a better penetration of media opacity such as cataract.

100000 A-scans/sec

The scan speed of the Topcon swept-source OCT is twice that of Spectral Domain-OCT devices. The DRI OCT-1 has 100000 A-scans/second compared with 50000 A-scans/second in an average SD-OCT, enabling faster acquisition of B-scans.

Invisible scan lines

An invisible scanning line due to the 1050 nm wavelength contributes to reduced patient eye motion, enhancing successful rates of scanning and fast examination workflow.

12 mm Wide scan

12 mm x 9 mm wide scan captures the macula and disc in the same scan, which is useful for the evaluation of abnormalities observed

in a broader area. Furthermore an instant single shot of the 12 mm wide area will reduce patient fatigue and tremendously enhance your examination workflow.



Topcon Europe Medical BV

Essebaan 11, 2908 LJ Capelle aan den IJssel, The Netherlands

Tel.: +31 10 4585077

E-mail: medical@topcon.eu

Website: www.topcon-medical.eu

Published in Ophthalmology Times Europe / Issue 3 2014